Biomedicine & Pharmacotherapy 148 (2022) 112710

Contents lists available at ScienceDirect

Biomedicine & Pharmacotherapy

journal homepage: www.elsevier.com/locate/biopha

Randomized trial of topical ascorbic acid in DMSO versus imiquimod for the treatment of basal cell carcinoma

Briant Burke [*,1,2], Jon-Eric Bailie

Center for Biomedical Research, Inc., Boise, ID 83706, USA

ARTICLE INFO

Keywords:
Basal cell carcinoma
Ascorbic acid
Vitamin c
Non-melanoma skin cancer
Basal cell cancer treatment

ABSTRACT

Skin cancer is the most common cancer in the United States and among Caucasians worldwide, with more people diagnosed each year than all other cancers combined. Basal cell cancer is the most common form with an estimated 4.3 million cases diagnosed annually, and treatment costs estimated at $4.8 billion. The objective of this study was to compare efficacy of a topical solution consisting of 30% ascorbic acid in 95% dimethylsulfoxide with topical imiquimod in the treatment of basal cell carcinoma. Twenty-five patients with 29 biopsy confirmed basal cell carcinomas were randomly assigned to receive either the topically applied ascorbic acid treatment twice daily for 8 weeks or topical imiquimod, a standard and well characterized topical treatment. After 8 weeks, post-treatment biopsy of lesions showed complete resolution of 13/15 (86.7%) in the ascorbic acid group, while 8/14 (57.1%) lesions in the IMQ group were resolved ($p < 0.05$ Chi Square). Topical ascorbic acid was superior at 8 weeks, and non-inferior at 12 weeks to topical imiquimod in the treatment of low risk nodular and superficial lesions. In addition, ascorbic acid was associated with fewer adverse effects than imiquimod. 70% of patients in the imiquinod group showed residual hypopigmentation at 30mo follow up versus 0% in the ascorbate group.

1. Introduction

Skin cancer is the most common cancer in the United States and among Caucasian peoples worldwide. More people are diagnosed each year with skin cancer than all other cancers combined [1,2], with basal cell cancer (BCC) being the most common form [3]. The annual cost of treating BCC in the US is estimated. at $4.8 billion [4]. The condition thus constitutes a significant health and cost burden to the US population. Task force consensus guidelines [5] on the treatment of BCC recommend Mohs surgery as the treatment of choice for many BCCs. However, cost and issues of cosmesis and scarring, particularly on the face, are principal disadvantages [5]. Topical treatments include the anti-neoplastic 5-fluoruracil (5-FU) and the immune response modifier imiquimod (Aldara®) [6–10].Efficacy rates for these treatments reportedly range from 35% to 75% [6–11], and imiquimod (IMQ) is associated with an incidence of residual hypopigmentation as high as 80% [12].

Ascorbic acid (AA) has a long and controversial history as an anti-neoplastic agent [summarized in [13]. However, reconsideration of its clinical potential has received credible scrutiny recently [13–15, reviewed,in,16], and clinical trials have revisited intravenous ascorbic acid as treatment for a variety of tumors [14–16]. In this study, we compared the efficacy of a topical concentrated ascorbic acid solution with IMQ in the treatment of low-risk BCC.

2. Methods

This trial was conducted in compliance with institutional guidelines for clinical trials and, was conducted in accordance with the principles of the Declaration of Helsinki, 2013 revision, regarding research with human subjects. Detailed informed consent was obtained from each patient and archived. Patients were recruited from primary care and dermatology clinics in the community. Eligible participants of any age had histologically confirmed primary nodular or superficial BCC, previously untreated, and not arising at sites of high risk for sub-clinical tumor spread (e.g., nose, ear, eyelid, eyebrow, vermillion border,

Abbreviations: AA, ascorbic acid; IMQ, imiquimod; DMSO, dimethylsulfoxide; BCC, basal cell cancer.

* Corresponding author.
E-mail address: bburkemd2@gmail.com (B. Burke).
[1] ORCID: 0000–0002-2843–2417
[2] Center for Biomedical Research, Inc. 967 E. Parkcenter Blvd Ste 205 Boise, ID 83706.

https://doi.org/10.1016/j.biopha.2022.112710
Received 7 December 2021; Received in revised form 26 January 2022; Accepted 7 February 2022
Available online 24 February 2022
0753-3322/© 2022 The Authors. Published by Elsevier Masson SAS. This is an open access article under the CC BY-NC-ND license (http://creativecommons.org/licenses/by-nc-nd/4.0/).

upper lip, scalp, or temple) [5]. Patients with infiltrative, recurrent, or morphoeic BCC, or history of malignancy of any kind, were excluded from the study.

Patients in the AA group were treated twice daily 7 days per week with a topical solution of 30% (w/v) ascorbic acid (Sigma-Aldrich Corp., USA) in 95% (v/v) dimethylsulfoxide (DMSO; Sigma-Aldrich Corp., USA) and 5% (v/v) distilled water, while the IMQ patients received application of a commercial 5% cream 5 days per week after the protocol of Vidal et al. [12]. The ascorbic acid solution was supplied in an amber glass bottle and applied at home by the patient using a cuticle brush. Volume of the ascorbic acid solution applied was 0.2–0.3 ml per application. Patients were randomly assigned to treatment group by blindly choosing a token numbered from 1 to 100 from a canister. Odd numbers were assigned to the AA treatment group and even to the IMQ group. Participants were blinded to treatment protocol. Patients were seen in the clinic at initial visit, 4 weeks, 8 weeks, and six weeks after treatment conclusion for final biopsy. In addition, patients were supplied every 2 weeks with a fresh solution of ascorbic acid to obviate issues surrounding stability. Those participants in the IMQ group who continued through 12 weeks of treatment were seen for an additional visit. The AA treatment was a solution while the IMQ a cream, however participants were simply told they would be receiving a topical treatment with instructions on how to apply, thus participant blinding remained intact. Primary outcome measure was the presence or absence of residual tumor at study conclusion as confirmed by 2 mm punch biopsy. Null hypothesis was that the AA treatment would be inferior to treatment with IMQ. Histopathology was confirmed by 2 mm partial punch biopsy leaving the bulk of the BCC intact prior to treatment.

Patient compliance in the AA cohort was high and no patient had difficulty with the application using the small brush. Treatment was continued for 8 wks or until the lesion cleared. Subjects in the IMQ group whose lesions had failed to resolve at 8 weeks were treated for an additional 4 weeks in conformity with reports showing better outcomes with 12 weeks of treatment with IMQ [11,17]. All patients had an appointment set for Mohs surgery after study enrollment, so in the event of treatment failure no further delay in definitive treatment would occur. Repeat 2 mm punch biopsy of each site was taken at the conclusion of the study. Patients were seen in follow up after 12, 24, and 30 months. Statistical analysis was by Chi square for enumerative data with 1 degree of freedom on intention-to- treat basis.

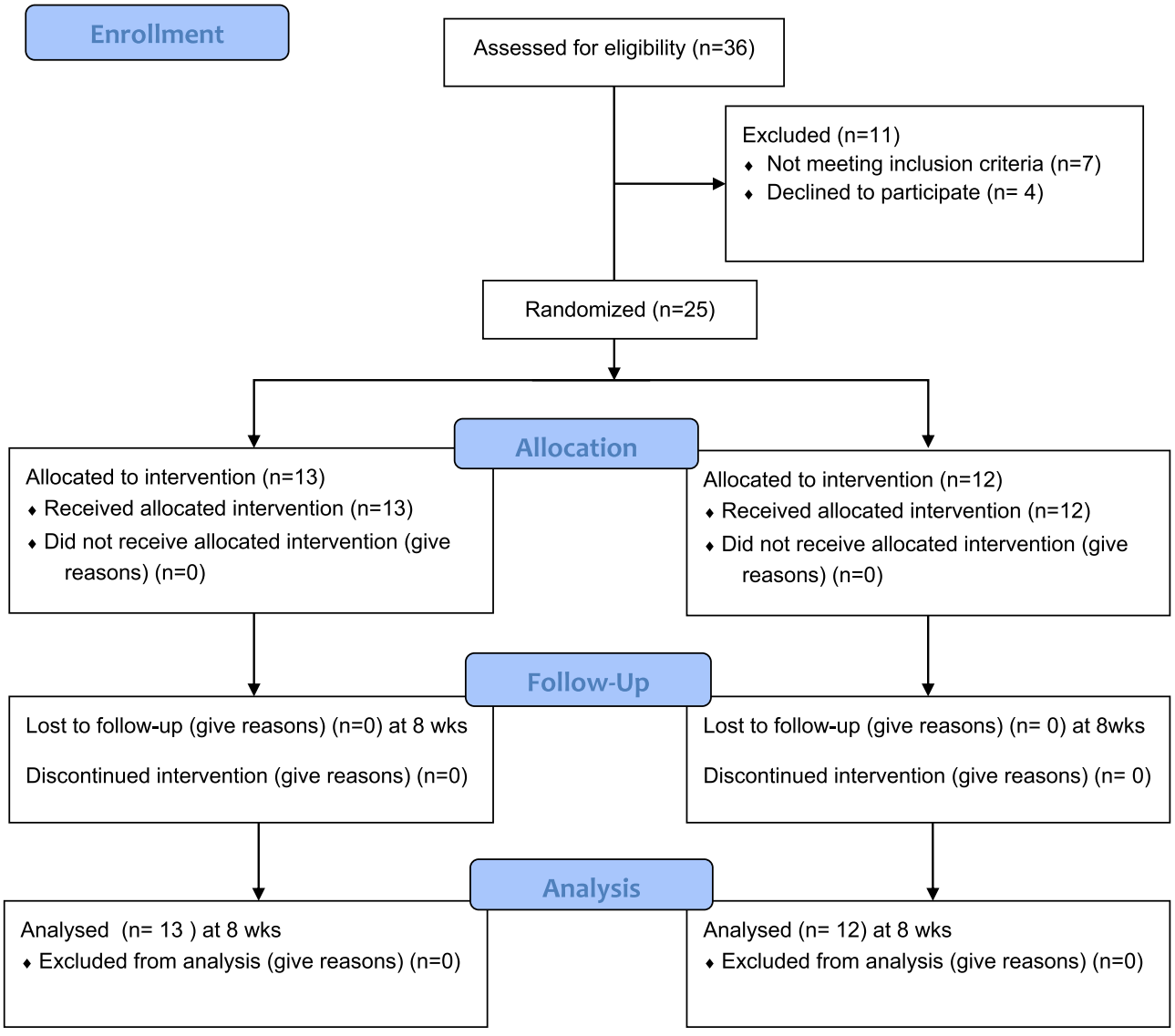

Fig. 1. Enrollment flow diagram.

3. Results

3.1. Enrollment

Thirty-six patients were assessed for eligibility, Fig. 1. Of those, 11 were excluded. Seven did not meet enrollment criteria and 4 declined to participate. Thirteen were allocated to the AA treatment arm and all 13 allocated received intervention. Twelve participants were allocated to the IMQ treatment arm and all 12 allocated received intervention. At 8 weeks no participant in either treatment arm was lost to follow up or discontinued treatment. Thirteen in the AA group were available for analysis after 8 weeks and all 12 in the IMQ after 8 weeks were also available for analysis. No patient at 8 weeks in either treatment arm were excluded from analysis. Table 1 shows baseline characteristics of each treatment group.

3.2. Histopathology

A total of 29 BCCs located on the trunk (14), extremities (9) and forehead (6) were treated. Lesions elsewhere above the neck were excluded from the study as potentially high risk. Histopathology showed 21 nodular and 8 superficial BCC subtypes upon enrollment. Thirteen patients (8 female 5 male) with a total of 15 lesions were randomized to the ascorbic acid (AA) treatment group, and 12 patients (6 female 6 male) with 14 lesions were randomized to the imiquimod group (IMQ). There was no difference in mean size of BCC in each group (11.4 +/−2.1 mm vs. 13.1 +/- 1.9 mm; mean +/- SE mean.Table 1). The AA group had 11 nodular and 4 superficial BCC and the IMQ group 10 nodular and 4 superficial.

After 8 weeks, post-treatment biopsy of lesions showed complete resolution of 13/15 (86.7%) in the ascorbic acid group, while 8/14 (57.1%) lesions in the IMQ group were resolved ($p < 0.05$ Chi Square). Six nodular lesions in the IMQ group failed to completely resolve after 8 weeks, and these were treated for an additional 4 weeks, at which time an additional 3 of the lesions had resolved. Thus, at 12 weeks 11/14 (78.6%) lesions in the IMQ group had resolved. This result is not different from the AA group at 8 weeks ($P > 0.1$). There was no sign of generalized inflammation or irritation of normal skin surrounding lesions in the AA group. Fig. 2 shows clinical improvement in a nodular BCC treated with the ascorbic acid preparation.

3.3. Adverse events and recurrence

Local skin irritation occurred at the majority of treatment sites in both groups, beginning with mild erythema followed by desquamation, superficial erosion (which was more pronounced in the imiquimod group), and re-epithelialization. After several days of use, patients reported mild stinging with application of the AA solution, which lasted for 1–2 min. Application of an OTC skin moisturizer alleviated the discomfort. No patient discontinued treatment due to adverse reaction or discomfort with either treatment, however 6 patients in the IMQ group developed enough pain with application that they were instructed to pause treatment for several days until symptoms abated, and then resume application. All patients with tumor free biopsy specimens were regularly monitored for clinical relapse. Over a 30-month observation period there were no recurrences in the AA group and 1 in the IMQ group, not a statistically significant difference. All patients enrolled completed the 8 week study, all were available at 12 month follow up and 20 were available for follow up at 30 months. There was no scarring or hypopigmentation observable in the AA treatment group 30 months after conclusion of treatment, however 7 subjects in the IMQ group (70%) showed residual hypo-pigmented areas. Most common adverse events were itching (85% in IMQ group vs. 57% in the AA group), pain (40% vs 8%), skin erosion (81% v 16%).

Table 1
Baseline Characteristics of Treatment Groups.

	Age	Male	Female	Lesion Size (mean +/-sem)
Ascorbic Acid Group	53.6 + /- 6.1 yr	5	8	11.4 + /− 2.1 mm
Imiquimod Group	56.9 + /- 8.5 yr	6	6	13.1 + /- 1.9 mm

4. Discussion

4.1. Mechanism of action

The mechanism of action of the current preparation against BCC was not explored. Indirect inflammation-related effects similar to the effect of topical imiquimod could be involved, although the inflammatory potential of ascorbic acid appears to be quite low [18]. Ascorbic acid has been reported to generate hydrogen peroxide in extracellular fluid, and this has been hypothesized to be part of its anti-neoplastic action via the Fenton reaction with increased levels of labile ferric iron in the tumor microenvironment [15,16]. Recently Ngo, et al. [16] evaluated pre-clinical evidence of redox imbalance, epigenetic re-programming and oxygen-sensing regulation as anti-neoplastic mechanisms of action of high dose ascorbate. Interestingly, the anti-metabolic effects of ascorbate have little effect on normal cells [16,19,20].

Using a 2 mm punch biopsy made it unlikely that any tumor was sufficiently debulked by the initial biopsy to affect treatment outcome.

4.2. Ascorbic acid

Ascorbic acid readily undergoes reversible oxidation to dehydroascorbate, both in vivo as part of physiological redox cycling, and in vitro upon exposure to oxygen [21]. The pH of the AA solution freshly prepared was 6.1–6.3. Because AA is an acid it is reasonably stable in acidic solution [21], however it can be rapidly oxidized by dissolved oxygen, which the solution was exposed to in the air each time the bottle was opened by the patient for application. To minimize issues with stability, participants were supplied with fresh solution every 2 weeks. The measured pH of the 2 week old AA solution remained at 6.1 – 6.3 range.

4.3. DMSO

A previous report by Hollo, et al. [22] demonstrated efficacy of a 33% saturated aqueous solution of ascorbic acid topically applied in the treatment of 7 BCCs. However, the protocol required the paste be applied under occlusion for 12 hrs. each day and, average time to lesion resolution was 22 wks rendering the treatment cumbersome and of little clinical utility. Subsequently the group used an IV ascorbate protocol for invasive BCC which lasted 42 wks [18]. Again, this represents a difficult protocol to comply with. The formulation in this study of 30% ascorbic acid in DMSO greatly reduced time to lesion resolution, although final results were similar to those found with an aqueous solution by Hollo, et al. [22]. Similar results in treating BCC in the absence of DMSO suggest the DMSO in the current formulation, while facilitating a much more rapid response, is not contributing any meaningful anti-neoplastic effects directly.

DMSO is a well characterized aprotic solvent known for its skin permeation enhancing abilities with a variety of solutes reviews [23–25]. It is known to have anti-inflammatory actions [23–25] and to act as a “maturation agent” in some neoplastic cell lines [reviewed in [24], however evidence of direct anti-cancer effect when applied topically is scant. The possibility of a synergistic effect between ascorbate and DMSO beyond enhanced penetration cannot be ruled out. DMSO has been used in combination with photodynamic therapy with 5-aminolevulinic acid (5-ALA) for treatment of BCC [26,27]. It was concluded



Fig. 2. Clinical improvement in a nodular BCC with twice daily topical application of 30% ascorbic acid in DMSO. Left: prior to biopsy and before treatment initiation. Center: 6 weeks after twice daily application. Right: complete resolution after 8 weeks of treatment.

that DMSO, with its unique solvent abilities, was being used to carry the 5-ALA further into the dermis in the hopes of being able to effectively treat non-melanoma skin cancers with less invasive means [26,27].

Each patient in the AA treatment group was only exposed to minute volumes of DMSO, approximately 400–600ul per day making risk of toxicity extremely unlikely.

4.4. Imiquimod

Imiquimod is an immune response modifier that has been successfully used to treat superficial BCC, for which it is FDA approved. It's use for treatment of nodular BCC has also been reported in multiple studies [6–9,10 review,12], although reported efficacy rates for nodular BCC vary widely. Use of imiquimod for nodular BCC is off label, nonetheless it is a convenient, topical treatment easily applied by the patient and these attributes, along with some proven efficacy, make it an appropriate treatment comparison for the current ascorbic acid formulation.

5. Study weaknesses

Weaknesses of the study include small sample size and a relative lack of ethnic diversity in the study subjects. Numbers in the study were too small to evaluate potential interactions between treatment effect and gender, race, tumor type, size, or skin classification. Potentially high-risk areas of the body were excluded from enrollment so the anatomic distribution of BCCs in the study did not reflect occurrence in the general population. It is unknown what the ascorbic acid/dehydroascorbic acid ratio was in the DMSO solution over time, or how this may have affected the solution's efficacy. Further, any role of DMSO beyond it's known permeation enhancement effects was not explored.

6. Conclusions

Management of BCC is dependent upon a variety of factors, including the location of the lesion, as tumors that arise in cosmetically or functionally important areas are best managed with treatments that minimize the amount of tissue removed while ensuring a high chance of complete cure [17]. Topical ascorbic acid was superior at 8 weeks, and non-inferior at 12 weeks to topical imiquimod in the treatment of low risk nodular and superficial BCC. In addition, ascorbic acid was associated with fewer adverse effects than imiquimod. Our results demonstrate that concentrated ascorbic acid in DMSO is a well tolerated, inexpensive, easy to use topical preparation that warrants larger clinical trials as a suitable first line treatment for BCC. Given its simplicity and lack of residual hypopigmentation it may find particular advantage for lesions on the face where issues of surgical scarring and cosmesis can be of paramount importance. This study describes a new topical treatment which could improve treatment outcomes and reduce costs for the most common cancer diagnosis in the US and worldwide. Larger clinical trials are warranted.

ClinicalTrials.gov Identifier

NCT04279535.

CRediT authorship contribution statement

Briant Burke: Conceptualization, Investigation, Data curation, Formal analysis, Project administration, Writing. **Jon-Eric Bailie**: Conceptualization, Supervision, Methodology, Validation, Writing – review & editing.

Conflict of interest statement

The authors declare that there are no conflicts of interest.

Data availability

Data will be made available on request.

Acknowledgements

Thanks to Marlene Rayne, MSW for editorial assistance with the manuscript.

Declaration of Interest

Neither author report any conflict of interest in this research or its publication.

References

[1] American Cancer Society. Cancer Facts and Figures 2019. Cancer.org. ⟨fhttps://www.cancer.org/research/cancer-facts-statistics/all-cancer-facts-figures/cancer-acts-figures-2019.html⟩ (accessed 12 July 2021).
[2] H.W. Rogers, M.A. Weinstock, S.R. Feldman, B.M. Coldiron, Incidence estimate of non-melanoma skin cancer (keratinocyte carcinomas) in the US population, 2012, JAMA Dermatol. 151 (10) (2015) 1081–1086, https://doi.org/10.1001/jamadermatol.2015.1187.
[3] American Cancer Society. Basal and squamous skin cancers. Cancer.org. ⟨http://www.cancer.org/cancer/skincancer-basalandsquamouscell/detailedguide/skin-

cancer-basal-and-squamous-cell-what-is-basal-and-squamous-cell⟩ (accessed 23 July 2021).
[4] G.P. Guy, S.R. Machlin, D.U. Ekwueme, K.R. Yabroff, Prevalence and costs of skin cancer treatment in the U.S., 2002-2006 and 2007-2011, Am. J. Prev. Med. 48 (2) (2015) 183–187, https://doi.org/10.1016/j.amepre.2014.08.036. Epub 2014 Nov 10.
[5] A.N. Kauvar, T. Cronin Jr., R. Roenigk, G. Hruza, R. Bennett, Consensus for non-melanoma skin cancer treatment: basal cell carcinoma, including a cost analysis of treatment methods, Dermatol. Surg. 41 (5) (2015) 550–571, https://doi.org/10.1097/DSS.0000000000000296.
[6] R.M. Schulstad, Case study: Imiquimod 5% cream in the treatment of a large nodular basal cell carcinoma, Dermatol. Nurs. 21 (2) (2009) 86–87. PMID: 19507375.
[7] J.A. Neville, P.M. Williford, J.L. Jorizzo, Pilot study using topical imiquimod 5% cream in the treatment of nodular basal cell carcinoma after initial treatment with curettage, J. Drugs Dermatol. 6 (9) (2007) 910–914. PMID: 17941362.
[8] K. Peris, E. Campione, T. Micantonio, G.C. Marulli, M.C. Fargnoli, S. Chimenti, Imiquimod treatment of superficial and nodular basal cell carcinoma: 12-week open-label trial, Dermatol. Surg. 31 (3) (2005) 318–323, https://doi.org/10.1111/j.1524-4725.2005.31081.
[9] S. Shumack, J. Robinson, S. Kossard, L. Golitz, H. Greenway, A. Schroeter, et al., Efficacy of topical 5% imiquimod cream for the treatment of nodular basal cell carcinoma: a comparison of dosing regimens, in: M Arch. Dermatol., 138, 2002, pp. 1165–1171, https://doi.org/10.1001/archderm.138.9.1165.
[10] C.M. Huang, M.G. Kirchhof, Topical imiquimod as a treatment option for nodular basal cell carcinoma: a systematic review, J. Cutan. Med Surg. 24 (5) (2020) 495–503, https://doi.org/10.1177/1203475420931770. Epub 2020 Jun 11. PMID: 32527151.
[11] F. Bath-Hextall, M. Ozolins, S.J. Armstrong, G.B. Colver, W. Perkins, P.S.J. Miller, H.C. Williams, Surgical excision versus 5% imiquimod cream for nodular and superficial basal cell carcinoma (SINS): a multicentre, non-inferiority, randomized controlled trial, Lancet Oncol. 15 (1) (2014) 96–105, https://doi.org/10.1016/S1470-2045(13)70530-8.
[12] D. Vidal, X. Matias-Guiu, A. Alomar, Fifty-five basal cell carcinomas treated with 5% Imiquimod: outcome at 5 year follow up, Arch. Derm. 143 (2) (2007) 264–276, https://doi.org/10.1001/archderm.143.2.266.
[13] J.J. Cullen, D.R. Spitz, G.R. Buettner, Comment on "Pharmacologic ascorbate synergizes with Gemcitabine in pre-clinical models of pancreatic cancer" i.e. All we are saying is, give C a chance, Free Radic. Biol. Med. 50 (2011) 1726–1727, https://doi.org/10.1016/j.freeradbiomed.2011.03.030.
[14] M.G. Espey, P. Chen, B. Chalmers, J. Drisko, A.Y. Sun, M. Levine, Q. Chen, Pharmacologic ascorbate synergizes with gemcitabine in preclinical models of pancreatic cancer, Free Radic. Biol. Med. 50 (2011) 1610–1619, https://doi.org/10.1016/j.freeradbiomed.2011.03.007. Epub 2011 Mar 12.
[15] J.D. Schoenfeld, M.S. Alexander, T.J. Waldron, Z.A. Sibenaller, D.R. Spitz, G. R. Buettner, B.G. Allen, J.J. Cullen, Pharmacological ascorbate as a means of sensitizing cancer cells to radio-chemotherapy while protecting normal tissue, Semin Radiat. Oncol. 29 (2019) 25–32, https://doi.org/10.1016/j.semradonc.2018.10.006.
[16] B. Ngo, J. Van Riper, L. Cantley, J. Yun, Targeting cancer vulnerabilities with high dose vitamin C, Nat. Rev. Cancer 19 (5) (2019) 271–282, https://doi.org/10.1038/s41568-019-0135-7.
[17] V. Smith, S. Walton, Treatment of facial basal cell carcinoma: a review, J. Ski. Cancer vol. 2011 (2011), 380371, https://doi.org/10.1155/2011/380371.
[18] A. Bánvölgyi, K. Lőrincz, N. Kiss, P. Avci, L. Fésűs, R. Szipőcs, T. Krenács, N. Gyöngyösi, N. Wikonkál, S. Kárpáti, K. Németh, Efficiency of long-term high-dose intravenous ascorbic acid therapy in locally advanced basal cell carcinoma – a pilot study, Post. Dermatol. Alergol. 39 (4) (2020) 548–558, https://doi.org/10.5114/ada.2019.83027. Epub 2019 Feb 26. PMID: 32994778.
[19] J. Yun, E. Mullarky, C. Lu, K.N. Bosch, A. Kavalier, K. Rivera, J. Roper, I.I. Chio, E. G. Giannopoulou, C. Rago, A. Muley, J.M. Asara, J. Paik, O. Elemento, Z. Chen, D. J. Pappin, L.E. Dow, N. Papadopoulos, S.S. Gross, L.C. Cantley, Vitamin C selectively kills KRAS and BRAF mutant colorectal cancer cells by targeting GAPDH, Science 350 (6266) (2015) 1391–1396, https://doi.org/10.1126/science.aaa5004. Epub 2015 Nov 5.
[20] Q. Chen, M.G. Espey, A.Y. Sun, C. Pooput, K.L. Kirk, M.C. Krishna, D.B. Khosh, J. Drisko, M. Levine, Pharmacologic doses of ascorbate act as a pro-oxidant and decrease growth of aggressive tumor xenografts in mice, Proc. Natl. Acad. Sci. USA 105 (32) (2008) 11105–11109, https://doi.org/10.1073/pnas.0804226105. Epub 2008 Aug 4.
[21] Vitamin C. ⟨http://sites.science.oregonstate.edu/chemistry/courses/ch130/old/VITCTEXT.htm⟩ (accessed 12 Jan 2022).
[22] P. Holló, H. Jókai, J. Hársing, G. Soós, S. Kárpáti, K. Németh, Topically applied ascorbic acid solution for the treatment of basal cell carcinoma (BCC), J. Am. Acad. Dermatol. 75 (1) (2016) 212–213, https://doi.org/10.1016/j.jaad.2016.04.003.
[23] C.F. Brayton, Dimethyl sulfoxide (DMSO): a review, Cornell Vet. 76 (1) (1986) 61–90. PMID: 3510103.
[24] E.N. Spremulli, D.L. Dexter, Polar solvents: a novel class of antineoplastic agents, J. Clin. Oncol. 2 (3) (1984) 227–241, https://doi.org/10.1200/JCO.1984.2.3.227. PMID: 6321692.
[25] K. Capriotti, J.A. Capriotti, Dimethyl sulfoxide: history, chemistry, and clinical utility in dermatology, J. Clin. Aesthet. Dermatol. 5 (9) (2012) 24–26. PMID: 23050031.
[26] E. Christensen, E. Skogvoll, T. Viset, T. Waroe, S. Sundstrom, Photodynamic therapy with. 5-aminolaevulinic acid, dimethylsulfoxide and curettage in basal cell carcinoma: a 6-year clinical and histological follow-up, J. Eur. Acad. Dermatol. Venereol. 23 (1) (2009) 58–66, https://doi.org/10.1111/j.1468-3083.2008.02946.x.
[27] C.S. Souza, L.B. Felicio, J. Ferreira, C. Kurachi, M.V. Bentley, A.C. Tedesco, V. S. Bagnato, Long-term follow-up of topical 5-aminolaevulinic acid photodynamic therapy diode laser single session for non-melanoma skin cancer, Photo Photo Ther. 6 (3–4) (2009) 207–213, https://doi.org/10.1016/j.pdpdt.2009.09.001.